F18-FCho, F-18 FET and F-18 FDG for the discrimination between tumor recurrence and radiation necrosis in high-grade glioma: a PET and autoradiography study.

Julie Bolcaen, Department of Radiology and Nuclear Medicine, UGent
On behalf of the UZGent Neuro-Oncology Research Group :
Julie Bolcaen, Ingeborg Goethals, Karel Deblaere (department of radiology and nuclear medicine)
Tom Boterberg (department of radiation therapy and experimental cancer research)
Filip De Vos (department of radiopharmacy)
Jean-Pierre Balala, Giorgio Vallaert (department of neurosurgery)
Caroline Van den Broecke (department of pathology)
Christian Vanhove, Benedicte Descamps (INFINITY lab, Ugent)

Glioblastoma (GB) is the most common primary malignant tumor of the central nervous system. The clinical course is usually rapid and fatal, with a median survival of approximately 1 year. For newly diagnosed patients with GB, the standard of care includes maximal surgical resection followed by combined radiation therapy (RT) and temozolomide (TMZ) [1]. An increased incidence of radiation necrosis (RN) is noted and may be attributed to the combined modality treatment. Differentiation of RN from recurrent brain tumor remains a diagnostic challenge. A correct diagnosis obviously has important implications for further management [2,3]. In case of RN steroids may suffice, while tumor recurrence necessitates second line treatment [2,3]. Currently, the differential diagnosis is confirmed by performing a biopsy. However, brain biopsy requires an invasive procedure that may have potential complications such as hemorrhage [2,3]. Conventional magnetic resonance imaging (MRI) has limitations because both types of lesions may have similar appearance [2,3]. Therefore, functional and biochemical imaging modalities are needed in addition to structural information [2,3]. Positron emission tomography (PET) may be able to distinguish RN from tumor recurrence and avoid a biopsy. Therefore we investigated the potential use of F-18 fluorodeoxyglucose (FDG), F-18 fluoromethylcholine (FCho) and F-18 fluoroethyltyrosine (FET), used to assess the glucose, choline and tyrosine metabolism. The value of these tracers has generally been evaluated in clinical studies in which pathological confirmation of either recurrent tumor or necrosis is not always available. Therefore, we started an in vivo study in which the uptake of these 3 PET tracers was investigated in a F98 GB rat model and a RN rat model using μPET and autoradiography. First, we developed a F98 glioblastoma rat model by inoculating 10000 tumor cells in the right frontal hemisphere. Day 10 after inoculation, a contrast-enhancing tumor was visible on MRI (Fig 1A). At that time point μPET and autoradiography was performed. Secondly, we developed an RN rat model. Using the small animal radiation research platform (SARRP), we irradiated the right frontal hemisphere with 30 Gy using 2 arcs of 10mm. γH2AX immunostaining confirmed the width of the beam. Irradiated rats had follow-up MRI scans that revealed a contrast-enhancing RN lesion after approximately 8 months (Fig1A). At that time point, μPET and autoradiography was performed. Based on the μPET data, the time activity curves (TACs) of the mean standard uptake values (SUV) and the lesion-to-normal tissue uptake ratios (LNR) were compared between GB and RN.

Based on our preliminary data, we found a statistically different uptaµe of 18F-FDG and 18F-FET between both groups. n ongoing worµ more data will be collected and immunostaining, ™suali¶ing the he®ɔµ¡nase and choline µ¡nase, will be performed to e®plain and confirm our results. The autoradiography data will be processed in the near future.

Figures.

Fig1.

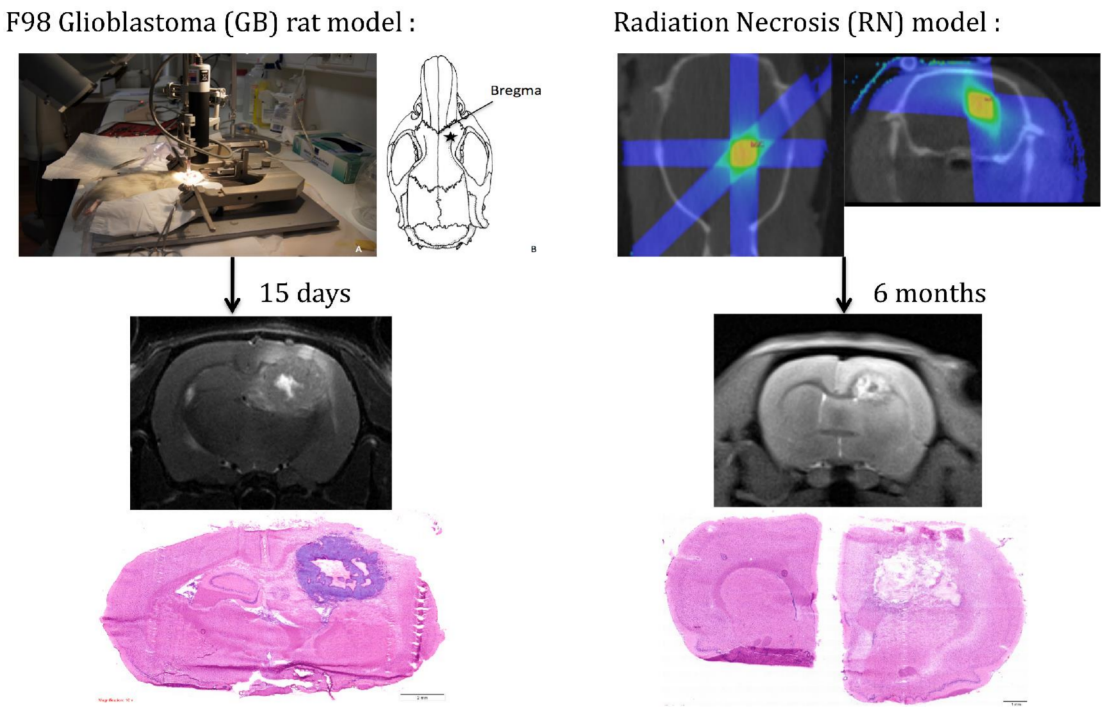

References.

1˜ fl nton ′ , Baehring JM, Mayer T. Glioblastoma multiforme: o™er™ew of current treatment and future perspecti™es. ematol Oncol Clin North fl m. Ó1ÓÂ ¯ :8-8.

¯˜ paeth N, … yss MT, … eber B, cheidegger , ′ ut¶ fl, erwey J, Rado™ano™c , Pahnµe J, … ild D, … estera G, … eishaupt D, ermann DM, ′ aser- ot¶ B, fl gu¶¶ fl , Bucµfl . Uptaµe of 18F-fluorocholine, 18F-fluoroethyl-′ -tyrosine, and 18F-FDG in acute cerebral radiation in ury in the rat: implications for separation of radiation necrosis from tumor recurrence. Journal of Nuclear Medicine. :1 1-1 8.

¯Ì˜ an ′ aere ′ , Ceyssens , an Calenbergh F, de Groot T, Menten J, Flamen P, Bormans G, Mortelmans ′ . Direct comparison of 18F-FDG and 11C-methionine PET in suspected recurrence of glioma: sensiti™ity, inter-obser™er ™ariability and prognostic ™alue. European Journal of Nuclear Medicine and Molecular maging. Ó ÎÂÌÓ :ÌÁ -Î 1.

¯Ï˜ Chao T, Õuh J , Ra a , ee «, Barnett G. The sensiti ity and specificity of FDG PET in distinguishing recurrent brain tumor from radionecrosis in patients treated with stereotactic radiosurgery. nternational Journal of Cancer. 1 :1 1-1 .

¯Î˜ Bobeµ-Billewic¶ B, tasiµ-Pres G, Ma chr¶aµ , Zarud ¶µ¡ T. Differentiation between brain tumor recurrence and radiation in ury using perfusion, diffusion-weighted imaging and MR spectroscopy. Folia Neuropathologica. 1 8 ¯ :81- .

¯˜ Tan , Chen ′ , Guan « , ′ in ». Comparison of MR , F-18 FDG, and 11C-choline PET CT for their potentials in differentiating brain tumor recurrence from brain tumor necrosis following radiotherapy. Clin Nucl Med. 11 : 8-81.